

# A Comparison of 3 Lasers and Liquid Nitrogen in the Treatment of Solar Lentigines

## A Randomized, Controlled, Comparative Trial

Michael M. Todd, MD; Tena M. Rallis, MD; John W. Gerwels, MD; Tissa R. Hata, MD

**Objective:** To determine if laser therapy is superior to liquid nitrogen for the treatment of solar lentigines and if so, to determine if one laser is superior to the other lasers that were tested.

**Design:** Randomized, controlled, comparative study with blinded observers.

**Setting:** University-based dermatology clinic.

**Participants:** Twenty-seven patients with multiple solar lentigines on the backs of both hands.

**Interventions:** Liquid nitrogen cryotherapy, the Medlite II frequency-doubled Q-switched Nd:YAG laser (Continuum Biomedical, Livermore, Calif), the HGM K1 krypton laser (HGM Medical Laser Systems Inc, Salt Lake City, Utah), and the DioLite 532-nm diode-pumped vanadate laser (Iridex Corp, Mountain View, Calif).

**Main Outcome Measures:** Photographs of the hands were taken prior to and 6 and 12 weeks following treatment. Blinded observers and patients evaluated each treat-

ment on its ability to lighten pigmented lesions without causing unwanted adverse effects.

**Results:** Many new laser systems claim an advantage for treating pigmented lesions by selectively destroying melanin. In this study, the frequency-doubled Q-switched Nd:YAG laser was most likely to provide significant lightening ( $P < .05$ ), followed by the HGM K1 krypton laser, the 532-nm diode-pumped vanadate laser, and liquid nitrogen. The frequency-doubled Q-switched Nd:YAG laser also had the fewest adverse effects ( $P < .05$ ), while the HGM K1 krypton laser had the most ( $P < .05$ ). Of the 27 patients, 25 preferred laser therapy to cryotherapy, with the frequency-doubled Q-switched Nd:YAG laser being the most popular.

**Conclusions:** Laser therapy is superior to liquid nitrogen for the treatment of solar lentigines. Of the laser systems tested in this study, the frequency-doubled Q-switched Nd:YAG laser is the most effective.

*Arch Dermatol.* 2000;136:841-846

**A**SOLAR LENTIGO is a benign pigmented lesion that occurs in sun-exposed areas of the face, arms, and hands. The lesions vary in size from 0.2 to 2.0 cm and become more numerous with advancing age. While lentigines are not premalignant lesions, they are aesthetically important to some patients.

Solar lentigines have been treated with a number of modalities, including topical tretinoin, cryotherapy with liquid nitrogen, bleaching agents, including hydroquinone, and more recently, laser surgery.<sup>1-5</sup> The theory of selective photothermolysis suggests that laser therapy would be the treatment of choice because of its ability to selectively destroy pigment without injuring surrounding tissue.<sup>6</sup>

Chromophores, molecules with unique absorption spectra, are responsible for imparting color to substances. The major chromophores of the skin are hemoglobin, oxyhemoglobin, carotene, and melanin. In solar lentigines, melanin is the chromophore causing the characteristic pigmented color and therefore is the target of selective destruction.<sup>7</sup>

### See also page 915

To obtain selective photothermolysis of melanin, pigmented lesions must be treated with laser light having a wavelength appropriate for the absorption spectrum of melanin. The absorption of melanin is highest in the UV range and decreases dramatically as the wavelength increases into the infrared region.<sup>1,7-9</sup> Thus,

From the Department of Dermatology, University of Utah School of Medicine, Salt Lake City.

## PATIENTS AND METHODS

Approval from the institutional review board at the University of Utah, Salt Lake City, was obtained to treat patients with solar lentigines according to the protocol described below. An explanation of the study, including the nature of the procedures, risks, benefits, and alternative treatment options, was provided, and informed written consent was obtained from all participants.

Patients were required to have at least 6 easily identifiable solar lentigines on the back of each hand. Other inclusion criteria included having a skin phototype of I to IV and agreeing to the protocol with follow-up. Patients who were pregnant, those older than 80 years, and those with primarily seborrheic keratoses on their hands were excluded. Twenty-seven patients were enrolled in the study and underwent treatment. Two patients were lost to follow-up.

The 4 treatment modalities used included cryotherapy with liquid nitrogen (application with a small-tip cotton applicator to each lesion for 5 seconds); Medlite II frequency-doubled Q-switched Nd:YAG laser (wavelength, 532 nm; 2.5 J/cm<sup>2</sup>; 5 Hz; 30 nanoseconds; 3-mm spot) from Continuum Biomedical (Livermore, Calif); HGM Spectrum K1 krypton laser (wavelength, 521 nm and 530 nm [green], 30.6 J/cm<sup>2</sup>, 1.2 W, 0.2 seconds on and 0.2 seconds off, 200 milliseconds, 1-mm spot) from HGM Medical Laser Systems Inc (Salt Lake City, Utah); and DioLite 532-nm, frequency-doubled, diode-pumped vanadate laser (wavelength, 532 nm; 13 J/cm<sup>2</sup>; 2.5 W; 5 Hz; 39 milliseconds; 1-mm spot) from Iridex Corp (Mountain View, Calif). Laser fluence, power, and pulse duration settings were based on manufacturer recommendations and previous clinical experience. Each method of treatment involved only one pass to each pigmented lesion with a 10% overlap of pulses.

The back of each hand was divided in half, creating a total of 4 treatment areas. Each half was treated with 1 of the 4 modalities so that every patient was treated with all 4 modalities. Treatment patterns were individually randomized. All areas to be treated with a laser had 4% tetracaine gel applied topically under

occlusion for 30 minutes prior to treatment. Areas treated with liquid nitrogen did not have anesthetic applied. Immediately after treatment with the frequency-doubled Q-switched Nd:YAG laser, tissue whitening was observed. Erythema was noted immediately after treatment with the other 3 modalities. Aquaphor ointment and a Telfa dressing were applied postoperatively. Patients were advised to keep a dressing of this type in place until their lesions healed and then to follow with sunscreen when outdoors.

Photographs were taken before treatment as well as 6 weeks and 12 weeks following treatment (**Figure 1**). The healing process was documented for a selected number of patients with more frequent photographs (**Figure 2**). All photographs were taken with the same Nikon N6006 camera, Nikon Speedlight SB-23 flash, and Kodak Elite II 100 film under similar positioning. Three blinded observers (J.W.G. and 2 others), all of whom were board-certified dermatologists, were asked to grade each treatment area individually. **Table 1** and **Table 2** contain observer data regarding lightening and adverse reactions at 6 and 12 weeks following laser treatment. Each laser type received a total of 75 observer grades (all 25 patients were graded by 3 observers) distributed among the 5 degrees of lightening and adverse reactions. The observers graded the methods of treatment based on a comparison of "before" and "after" pictures at 6 and 12 weeks viewed simultaneously by dual projection. The grading scale consisted of rating the degree of lightening (percentage of clearing) as designated by the following 5-point grading scale: poor, 0% to 25%; fair, 26% to 50%; good, 51% to 75%; excellent, 76% to 90%; and clear, 91% to 100%. Additionally, observers were asked to note unwanted adverse effects when present, including erythema (on a scale of 1 to 4, with 1 minimal and 4 severe), hypopigmentation, hyperpigmentation, scarring, and textural change. The clinical end point of treatment was complete lightening without unwanted adverse effects.

Six weeks following the treatments, patients were asked to select the treatment that achieved the best result in their opinion. They were also asked to identify the procedure that was most painful and the treatment area that was quickest to heal.

one would expect lasers with shorter wavelengths to be more effective in selectively removing melanin from skin. The frequency-doubled Q-switched Nd:YAG laser has a wavelength of 532 nm. The 532-nm emitting diode laser also has a wavelength of 532 nm, which is achieved by using a diode energy source to optically pump a vanadate laser crystal. The 1064-nm laser light is then focused into a doubling crystal to produce the 532-nm wavelength. The krypton laser is used with the green setting that emits wavelengths of 521 and 530 nm. The wavelength range of all of these lasers is well absorbed by melanin, suggesting that all 3 of these lasers may be effective in treating solar lentigines.<sup>7</sup>

Equally important in achieving selective photothermolysis of melanin is the pulse duration. Ideally, the pulse duration of the laser should be shorter than the thermal relaxation time of melanin to achieve selective photothermolysis. The frequency-doubled Q-switched Nd:

YAG laser has a pulse duration of 30 nanoseconds, the shortest pulse duration of the 3 lasers, since it is Q-switched. The 532-nm emitting diode laser is able to produce a pulse duration of 10 to 40 milliseconds. The krypton laser is a continuous-wave laser operated with mechanical pulsing (gating) and has a pulse duration greater than 100 milliseconds.

Numerous lasers, including the frequency-doubled Q-switched Nd:YAG laser, have been shown to be effective for the treatment of benign pigmented lesions.<sup>1,10</sup> Few published data exist on the effectiveness of the 532-nm emitting diode lasers and krypton lasers.<sup>11,12</sup>

While the reasons mentioned above would indicate a theoretical advantage for laser therapy over more traditional modalities like liquid nitrogen, the purpose of this study was to determine if the theoretical advantage of lasers would in fact hold true in the clinical setting.

## RESULTS

Both hands of 27 patients were treated with 4 different modalities. All 27 patients returned for the 6-week follow-up and completed the patient survey. Two patients were lost to follow-up at 12 weeks. Table 1 contains raw observer data regarding lightening at 6 and 12 weeks postoperatively. Statistics were obtained using Wilcoxon signed nonparametric analysis. Interobserver variability was not found to be significant when lightening grades assigned at 12 weeks were analyzed via the Fisher protected least significant difference method. The cutoff was  $P < .05$ .

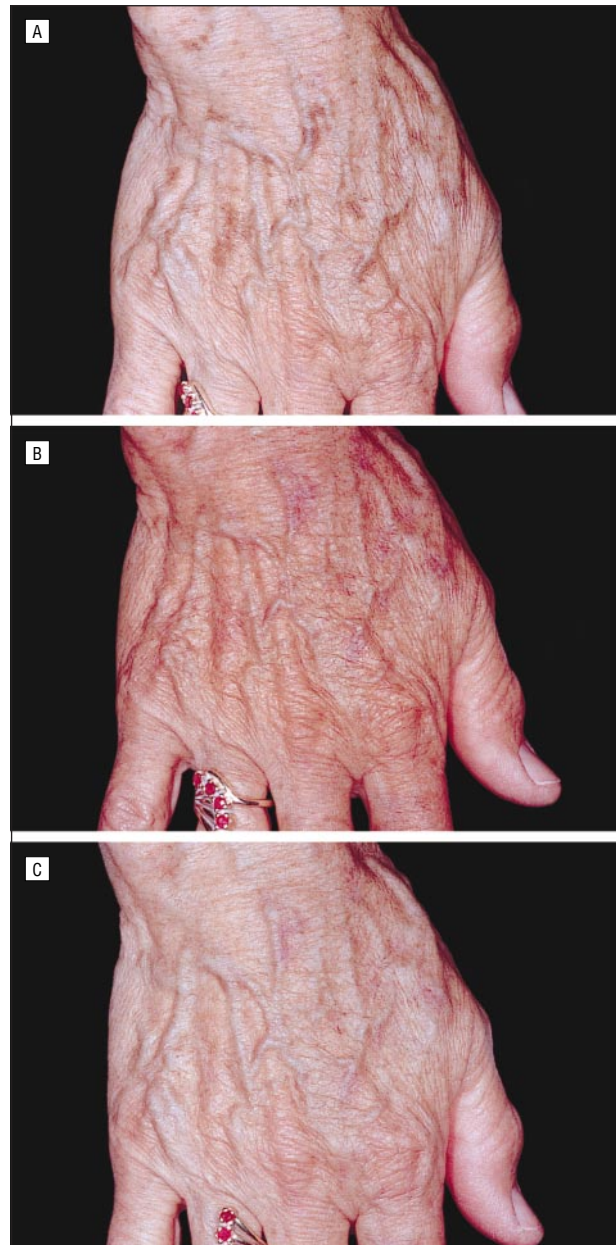
Six weeks following treatment, the frequency-doubled Q-switched Nd:YAG laser was found to provide superior lightening when compared with liquid nitrogen ( $P < .001$ ), the 532-nm emitting diode laser ( $P < .001$ ), and the krypton laser ( $P = .183$ ) (Figure 3). At 12 weeks postoperatively, the frequency-doubled Q-switched Nd:YAG laser was again shown to achieve results significantly superior to those of liquid nitrogen ( $P < .001$ ), the 532-nm emitting diode laser ( $P < .001$ ), and the krypton laser ( $P < .001$ ). Additionally, the krypton laser was more likely to produce lightening than liquid nitrogen at the 12-week follow-up ( $P < .179$ ) (Figure 4).

Analysis of the unwanted adverse effects found at 6 weeks indicates that the krypton laser was more likely to produce erythema than the other modalities studied ( $P < .001$ ), according to Wilcoxon signed nonparametric analysis. Twelve weeks following treatment, the krypton laser produced significantly more erythema than the frequency-doubled Q-switched Nd:YAG laser and liquid nitrogen ( $P < .001$ ). Data regarding unwanted adverse effects are in Table 2.

Considering that the treatment of solar lentigines is a cosmetic therapy performed primarily to please the patient, perhaps some of the most valuable information obtained in this study is the patient survey (Table 3). All 27 patients who underwent therapy completed the patient survey 6 weeks following treatment. Subjects were asked which of the 4 treatment modalities provided the overall best result. Six weeks following treatment, 25 (93%) of the 27 patients felt that laser therapy provided the overall best result, while 2 patients (7%) preferred liquid nitrogen. Of the 25 who chose laser therapy, 18 (72%) preferred the results achieved by the frequency-doubled Q-switched Nd:YAG laser, 6 patients (24%) selected the 532-nm emitting diode laser, and 1 patient chose the krypton laser.

In addition, patients were asked to indicate which treatment area was quickest to heal. Of the 27 patients, 16 (59%) felt that the area treated by the frequency-doubled Q-switched Nd:YAG laser was the quickest to heal (Table 3). Patients were not required to specify the healing times.

Finally, patients were asked to identify the most painful treatment. All areas that were treated with a laser had 4% tetracaine gel applied under occlusion for 30 minutes prior to the procedure. Areas treated with liquid nitrogen received no topical anesthetic. Patients were asked to select the most painful treatment irrespective of whether or not anesthetic was applied. Two patients (7%) were unable to distinguish differences in pain and did not an-

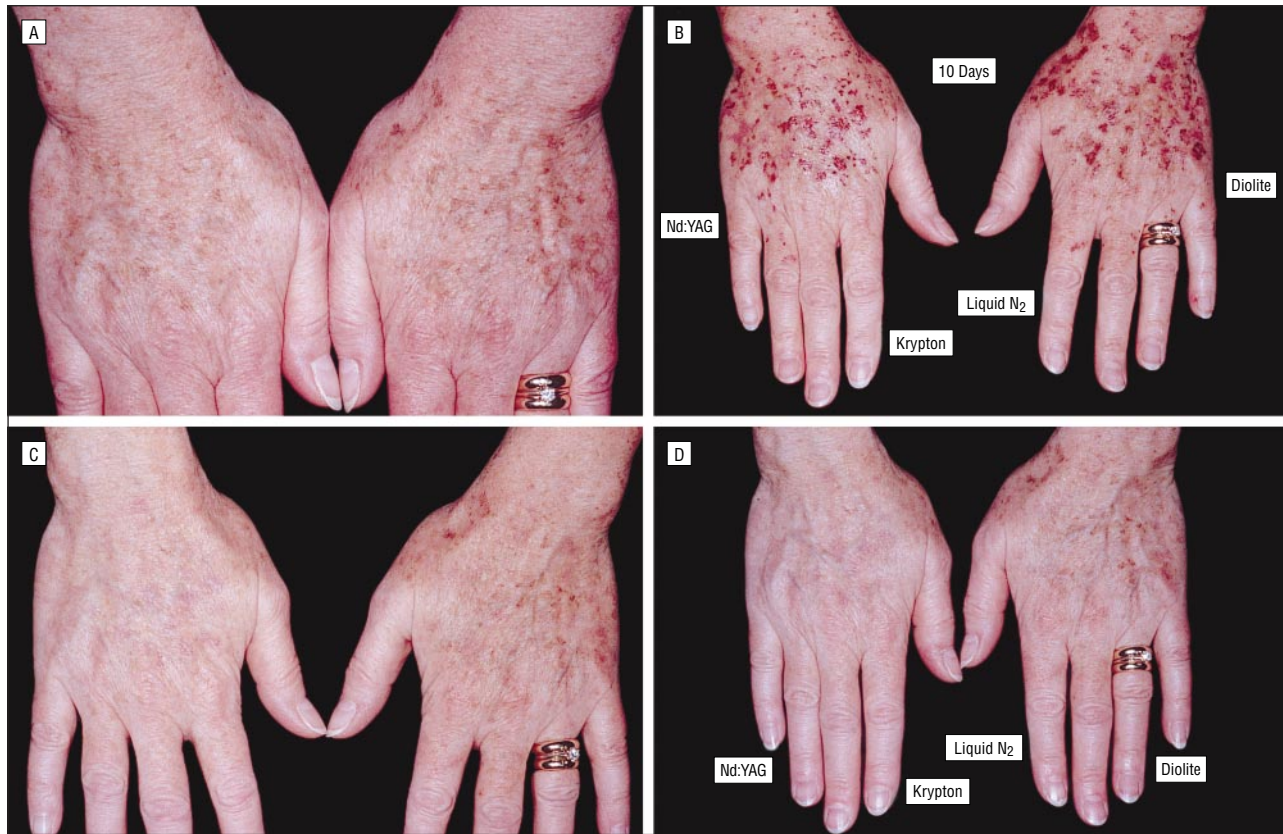

**Figure 1.** Right hand of a 67-year-old woman preoperatively (A) and 6 weeks (B) and 12 weeks (C) following treatment. The medial half of the hand was treated with a krypton laser and the lateral half with a frequency-doubled Q-switched Nd:YAG laser.

swer this question. Of the 25 patients who did respond, 15 (60%) felt that the krypton laser was the most painful.

## COMMENT

Of the modalities tested, the frequency-doubled Q-switched Nd:YAG laser was clearly the most effective therapy for the treatment of solar lentigines. It was more likely to produce significant lightening and at the same time was less likely to produce unwanted adverse effects. The frequency-doubled Q-switched Nd:YAG laser was the most popular among patients in all 3 categories assessed; more patients felt it gave a better



**Figure 2.** Solar lentigines on both hands of a 50-year-old woman preoperatively (A), 10 days after undergoing treatment, with labels indicating corresponding treatment areas (B), and 6 weeks (C) and 12 weeks (D) following treatment. Diolite indicates 532-nm diode-pumped vanadate laser.

**Table 1. Lightening of Lentigines by Treatment at 6 and 12 Weeks as Determined by Physician Evaluation (N = 75)\***

Treatment	Observer Grades, %				
	Poor (0%-25%)	Fair (26%-50%)	Good (51%-75%)	Excellent (76%-90%)	Clear (91%-100%)
<b>6 Weeks</b>					
Liquid nitrogen	8	7	20	44	21
Q-switched Nd:YAG laser	4	3	10	36	47
Krypton laser	3	5	18	47	27
Diode-pumped vanadate laser	3	8	22	43	24
<b>12 Weeks</b>					
Liquid nitrogen	8	9	15	44	24
Q-switched Nd:YAG laser	0	3	8	29	60
Krypton laser	1	5	14	48	32
Diode-pumped vanadate laser	0	9	20	44	28

\*Each laser type received a total of 75 observer grades (all 25 patients were graded by 3 observers) distributed among the 5 degrees of lightening.

result, healed quicker, and was less painful than the other therapies.

These results indicate that the frequency-doubled Q-switched Nd:YAG laser selectively destroyed melanin while preserving surrounding tissue. In addition to the appropriate wavelength, selective photothermolysis requires a laser to have a pulse duration that is shorter than the thermal relaxation time of the targeted chromophore. The frequency-doubled Q-switched Nd:YAG laser is the only laser with a pulse duration less than the thermal relaxation time of a

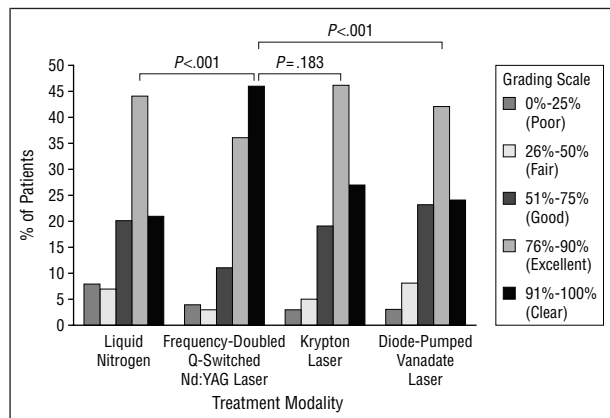
melanosome (estimated at 10-100 nanoseconds).<sup>13</sup> This may explain why it produced superior results.<sup>6,14</sup> It is also possible that the larger 3-mm spot size of the frequency-doubled Q-switched Nd:YAG laser contributed to the superior results obtained compared with the other laser systems, which used a smaller 1-mm spot size, since larger spot sizes have been shown to have a deeper penetration than smaller spot sizes.<sup>15</sup>

The 532-nm emitting diode laser showed similar lightening of pigmented lesions as the liquid nitrogen, and the adverse effects were slightly more common than

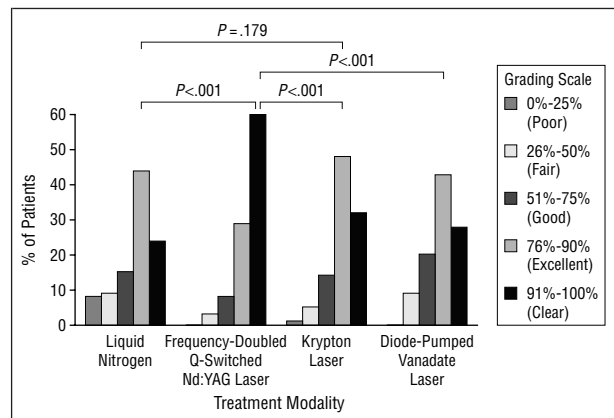
**Table 2. Patients With Adverse Reactions by Treatment at 6 and 12 Weeks as Determined by Physician Evaluation (N = 75)\***

Treatment	Observer Grades, %							
	Erythema				Hyperpigmentation	Hypopigmentation	Scarring	Textural Change
	Minimal	Mild	Moderate	Severe				
<b>6 Weeks</b>								
Liquid nitrogen	25	13	1	0	1	0	0	1
Q-switched Nd:YAG laser	24	7	3	0	1	1	0	0
Krypton laser	17	28	24	1	0	0	1	11
Diode-pumped vanadate laser	32	16	7	0	1	2	1	2
<b>12 Weeks</b>								
Liquid nitrogen	19	1	0	0	0	1	0	4
Q-switched Nd:YAG laser	17	0	0	0	1	1	0	2
Krypton laser	35	12	2	0	2	4	2	8
Diode-pumped vanadate laser	27	7	1	0	0	1	0	7

\*Each laser type received a total of 75 observer grades (all 25 patients were graded by 3 observers) distributed among the adverse reactions.



**Figure 3.** Percentage of clearing by treatment modality at 6 weeks following treatment.



**Figure 4.** Percentage of clearing by treatment modality at 12 weeks following treatment.

with cryotherapy. However, patients generally liked the 532-nm emitting diode laser. It was the second most popular method of treatment after the frequency-doubled Q-switched Nd:YAG laser.

The krypton laser was superior at lightening pigmented lesions when compared with liquid nitrogen, but it was far more likely to produce erythema and other unwanted adverse effects at the settings used in this study. Most patients felt it was the most painful of the modalities used.

Liquid nitrogen is not an unreasonable alternative to laser therapy. While it was not as likely to produce desired lightening, it was also not as likely to produce unwanted adverse effects compared with the krypton and diode lasers. It is certainly inexpensive and accessible. This study compared modalities based on one-time treatment only. Repeated treatments with liquid nitrogen could yield better results than those obtained with the one-time treatment protocol of this study. Additionally, the relative scarcity of adverse effects would make repeated treatments an acceptable approach.

At the beginning of this study, we asked if the theoretical advantage of selective photothermolysis would hold true for the treatment of solar lentigines. Indeed, this study provides evidence that the theoretical advantage of selective photothermolysis through laser therapy actually

**Table 3. Patient Survey Results by Treatment**

	No. (%) of Patients		
	Best Result (n = 27)	Healed Quickest (n = 27)*	Most Painful (n = 25)
Liquid nitrogen	2 (7)	3 (11)	4 (16)
Q-switched Nd:YAG laser	18 (67)	16 (59)	2 (8)
Krypton laser	1 (4)	2 (7)	15 (60)
Diode-pumped vanadate laser	6 (22)	6 (22)	4 (16)

\*Percentages do not add to 100% because of rounding.

holds true in the clinical setting. The best example of this is the frequency-doubled Q-switched Nd:YAG laser with its appropriate wavelength and short pulse duration. As new lasers are rapidly being developed, in the future we expect to see laser surgery become even more superior to traditional methods.

Accepted for publication December 10, 1999.

The results of this research were presented at the American Society for Laser Surgery and Medicine Meeting, Orlando, Fla, April 18, 1999.

Corresponding author: Tissa R. Hata, MD, Department of Dermatology, University of Utah, 50 N Medical Dr, Room 4B454, Salt Lake City, UT 84132 (e-mail: tissa@ultraderm.med.utah.edu).

## REFERENCES

1. Kilmer SL, Wheeland RG, Goldberg DJ, Anderson RR. Treatment of epidermal pigmented lesions with the frequency-doubled Q-switched Nd:YAG laser: a controlled, single-impact, dose-response, multicenter trial. *Arch Dermatol*. 1994;130:1515-1519.
2. Fitzpatrick RE, Goldman MP, Ruiz-Esparza J. Laser treatment of benign pigmented epidermal lesions using a 300 nsecond pulse and 510 nm wavelength. *J Dermatol Surg Oncol*. 1993;18:341-347.
3. Goldberg DJ. Benign pigmented lesions of the skin: treatment with the Q-switched ruby laser. *J Dermatol Surg Oncol*. 1993;19:376-379.
4. Dinehart SM, Wane M, Flock S. The copper vapor laser for treatment of cutaneous vascular and pigmented lesions. *J Dermatol Surg Oncol*. 1993;19:370-375.
5. Stern RS, Dover JS, Levin JA, Arndt, KA. Laser therapy versus cryotherapy of lentigines: a comparative trial. *J Am Acad Dermatol*. 1994;30:985-987.
6. Anderson RR, Parrish JA. Selective photothermolysis: precise microsurgery by selective absorption of pulsed radiation. *Science*. 1983;220:524-527.
7. Spicer MS, Goldberg DJ. Lasers in dermatology. *J Am Acad Dermatol*. 1996;34:1-25.
8. Sherwood KA, Murray S, Kurban AK, Tan OT. Effect of wavelength of cutaneous pigment using pulsed irradiation. *J Invest Dermatol*. 1989;92:717-720.
9. Murphy GF, Shepard RS, Paul BS, et al. Organelle-specific injury to melanin-containing cells in human skin by pulsed laser irradiation. *Lab Invest*. 1987;49:680-685.
10. Tse Y, Levine VJ, McClaine SA, Ashinoff R. The removal of cutaneous pigmented lesions with the Q-switched neodymium: yttrium-aluminum-garnet laser. *J Dermatol Surg Oncol*. 1994;20:795-800.
11. Thibault PK. A patient's questionnaire evaluation of krypton laser treatment of facial telangiectases. *Dermatol Surg*. 1997;23:37-41.
12. Wheeland RG. Treatment of port-wine stains for the 1990s. *J Dermatol Surg Oncol*. 1993;19:348-356.
13. Goldman MP, Fitzpatrick RE. Treatment of benign pigmented cutaneous lesions. In: *Cutaneous Laser Surgery: The Art and Science of Selective Photothermolysis*. St Louis, Mo: Mosby-Year Book; 1994:106-141.
14. Lanigan SW. Port-wine stains unresponsive to pulsed dye laser: explanations and solutions. *Br J Dermatol*. 1998;139:173-177.
15. Kilmer SL, Farinelli W, Tearney G, et al. Use of a larger spot size for the treatment of tattoos enhances the clinical efficacy and decreases potential side effects [abstract]. *Lasers Surg Med Suppl*. 1994;6:5.