

Introduction

Visible light therapy has historically been used to treat a broad range of skin and soft tissue disorders and is particularly useful in the treatment of chronic wounds^{1,2}. Low energy level light therapy, and its resulting beneficial responses, are based on a biological process known as photobiomodulation (PBM)³.

The process of PBM is based on evidence that photons are able to activate photoacceptors within cells and tissue, which consequently induce molecular cascades, modulating several aspects of cell biology¹⁻³. PBM therapeutic techniques include low-level laser, light-emitting diode (LED) and broadband visible light lamps.

PBM therapies have been shown to positively affect all stages of the wound healing process, encouraging granulation and new tissue growth⁴. PBM also kickstarts natural production of nitric oxide (NO), which is an anti-inflammatory agent and provides pain relief⁵.

Authors: Andreas Nikolis, Giovanni Scapagnini and Marco Romanelli. Full author details can be found on page 5.

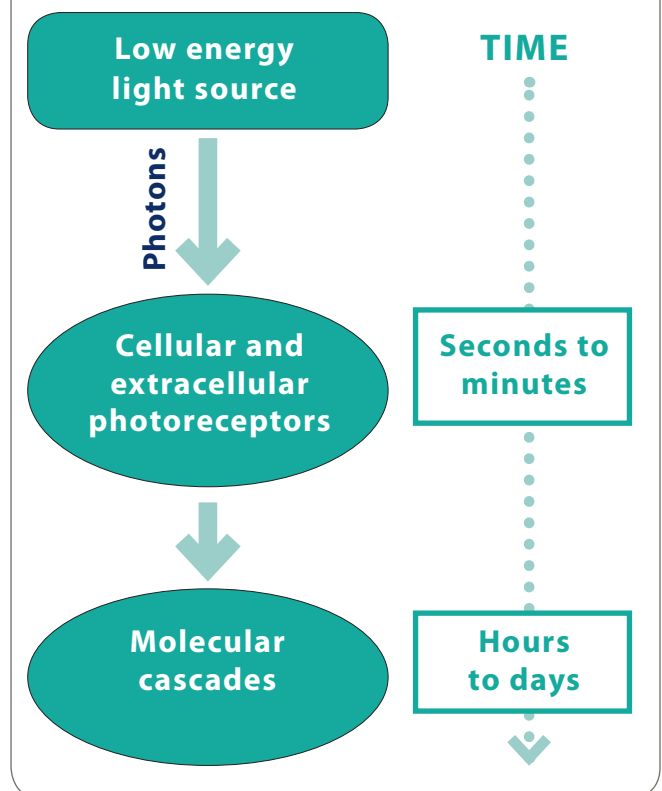
Understanding PBM in wound healing

Experimental and clinical studies have shown that PBM has a beneficial effect on all stages of the wound healing process^{4,5}. Interaction of light and biological tissues is mediated by photoreceptors; both intracellular and extracellular photoreceptors induce specific signal transduction pathways that recruit transcription factors, leading to a concerted gene expression and contributing to therapeutic PBM effects on wound healing (Figure 1).

In the inflammatory and proliferative phases, PBM enhances proliferation of specific cells, including fibroblasts, keratinocytes, osteoblasts, and chondrocytes, as well as inducing matrix synthesis⁶.

In the maturation phase, PBM encourages renewed tissue growth and improves tissue quality⁷. Additionally, wound healing is promoted via prevention of apoptosis, increase in blood flow, and stimulation of angiogenesis, as well as

Figure 1 | The mechanisms of photobiomodulation (PBM)



increase in adenosine triphosphate (ATP) and cyclic adenosine monophosphate (cAMP)⁸.

The biological reactions caused by exposure to PBM result in the production of nitric oxide (NO), a vasodilator and powerful pain reliever, and anti-inflammatory agent⁵. In particular, the anti-inflammatory effects of PBM induce modulation of nuclear factor kappa-B (Nf-kB), which control both pro- and anti-inflammatory factors, such as interleukin-1 (IL-1), IL-8, cyclooxygenase-1 (COX-1), and COX-2⁹⁻¹¹.

An important growth factor activated by PBM mechanisms is the transforming growth factor- β (TGF- β). TGF- β plays a crucial role in the proliferation and regrowth of the wound tissue by promoting keratinocytes, endothelial, and fibroblast cell migration¹². It has also been shown that PBM may regulate vascular endothelial growth factor (VEGF), enhancing the formation of new vessels and improving the healing of skin¹³.

In recent years, clinical studies have focused on the use of PBM therapy in chronic wounds. Chronic wounds are defined as

Photobiomodulation with LumiHeal™ made easy



'wounds which have failed to proceed through an orderly and timely reparative process to produce anatomic and functional integrity over a period of three months'¹⁴.

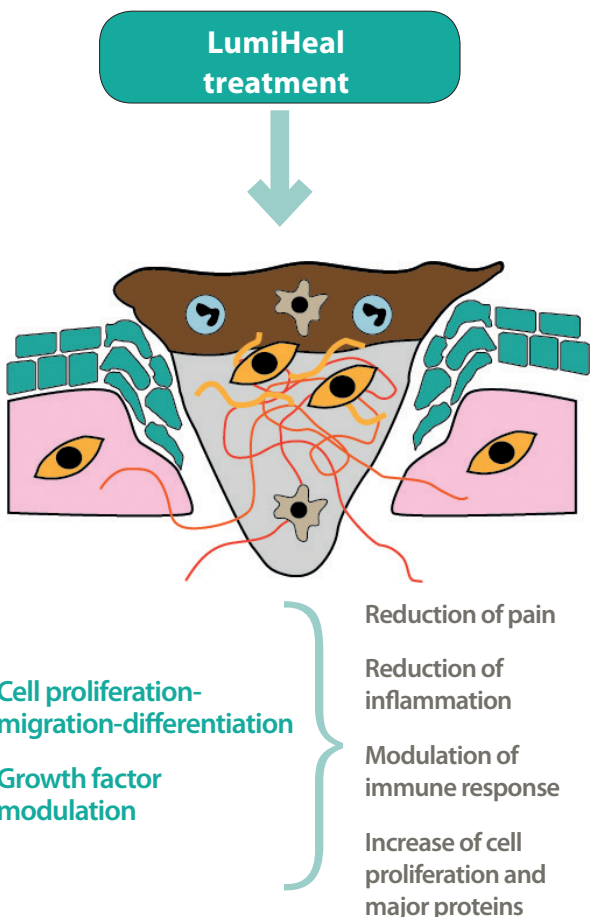
A double-blind randomised placebo-controlled study was conducted to assess the effect of phototherapy in chronic diabetic leg ulcers¹⁵. This study demonstrated that the light's mode of action promotes rapid granulation and healing of diabetic ulcers that had previously failed to respond to other forms of treatment.

A further pilot prospective case-series study assessed the effectiveness of polarised, polychromatic, non-coherent light therapy in the treatment of venous leg ulcers. At the end of four weeks of treatment, the biopsied specimens of leg ulcers showed significant histological changes, including re-epithelialisation, new blood vessels and extensive collagen deposition¹⁶.

The effect of LED phototherapy was also studied in patients with chronic venous ulcers that had previously been considered unresponsive to conventional therapies¹⁷. This study concluded that phototherapy accelerates the healing process of chronic venous ulcers, demonstrating that ulcers treated with the full dose of 660 nm and 890 nm light healed faster than those in the control group.

The most prevalent form of PBM to date has used low-level lasers and LEDs, mostly in the red and near infra-red range. However, because the absorption bands of cytochrome oxidase and other photoreceptors are relatively wide, broadband light is currently being explored as a possible better approach in the field of wound healing. A placebo-controlled double-blind study investigated the efficacy of a broadband (400–800 nm) visible light device in the treatment of leg or foot ulcers¹⁸. This study demonstrated that visible light was an effective treatment for chronic leg or foot ulcers in diabetic patients.

Figure 2 | The effect of LumiHeal treatment on chronic wounds



Introducing LumiHeal™: a novel BioPhotonic treatment

LumiHeal™ (Klox Technologies) is designed to create an environment that promotes the healing of chronic and

Figure 3 | Proposed mode of action of LumiHeal

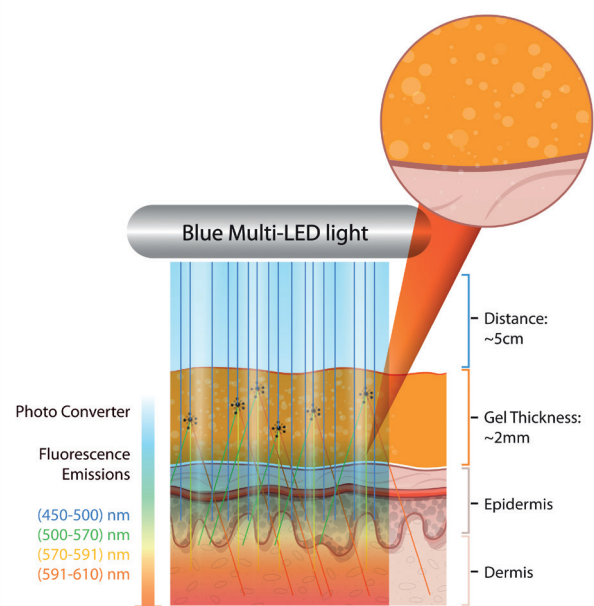


Figure 4 | Pain scores in 10 patients receiving treatment with LumiHeal¹⁹

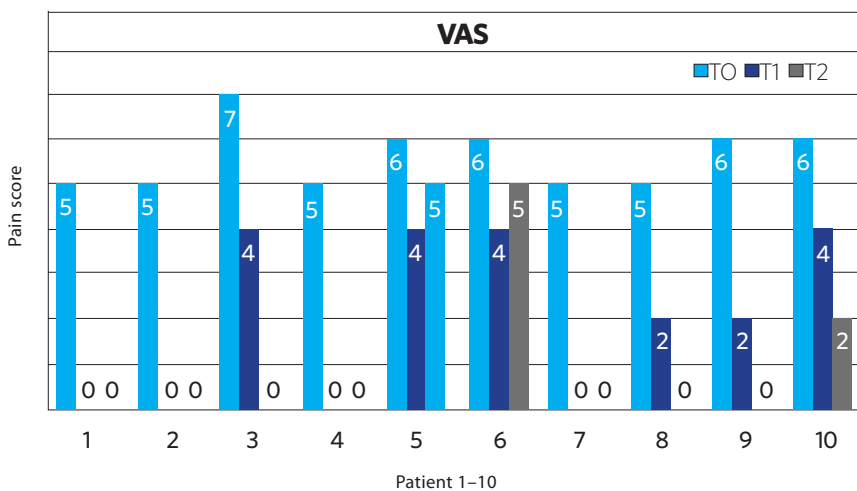
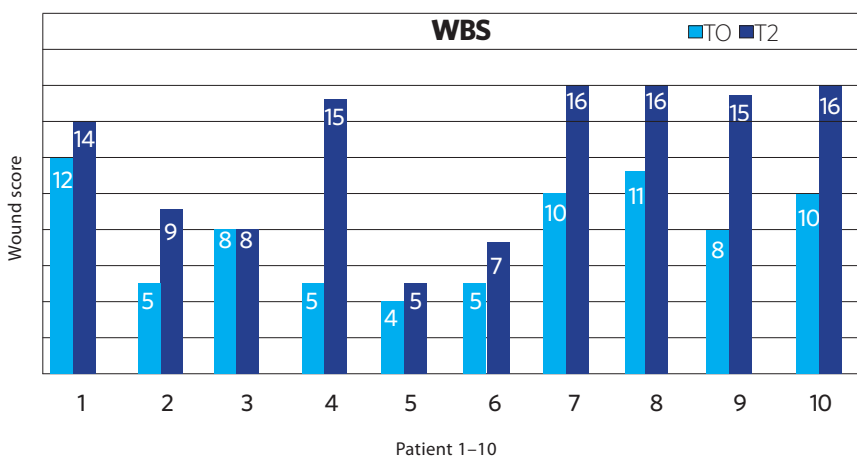


Figure 5 | Wound bed scores in 10 patients receiving treatment with LumiHeal¹⁹



with the wavelengths emitted from the multi-LED lamp, in order to maximise the beneficial effects of PBM on promoting wound healing ¹⁹ (Figure 2, Figure 3).

In vitro and *in vivo* experimental studies have shown that the BioPhotonic process activates, in a novel way, several pathways related to an improvement of the wound healing process²⁰.

Early clinical studies have demonstrated that the LumiHeal treatment is particularly suitable for treating chronic wounds, where previous treatments have not been effective¹⁹.

In a recent study, a total of 10 patients with chronic venous leg ulcers that were non-responsive to standard treatments were treated twice a week for four months with the LumiHeal treatment¹⁹. The gel was applied to the wound bed and was illuminated for five minutes. After treatment the wound bed was cleansed using saline solution and moisture-balancing dressings, along with a short compression bandaging system. The wounds were evaluated once a week, in terms of wound size, wound bed evaluation, and pain scores.

Of the 10 patients, by the end of the study, three patients had completely healed and four had achieved a significant improvement in wound size. After one week of treatment, pain scores in all patients improved (Figure 4) and the wound bed score had improved in nine of the 10 patients (Figure 5). These preliminary data suggest that the LumiHeal treatment is effective, safe and provides an improvement in patients' quality of life.

The efficacy of the LumiHeal treatment on chronic wounds was confirmed

acute wounds including surgical wounds and burns. This new technology, based on the principles of BioPhotonic treatment, consists of a light-emitting diode (LED) lamp and a photoconverter gel, which is topically applied. The gel contains light-absorbing molecules (chromophores), which are not absorbed by the skin but,

when activated with a LED light, release photons at different wavelengths in the spectra of visible light, from 532 to 615 nm. These special molecules are compounds able to be activated by light and to re-emit photons as fluorescence.

These low-energy photons, together with other properties of the gel, act

by another case study in 10 patients with venous leg ulcers, whose wounds had failed to progress on at least one previous standard of care treatment²¹. Efficacy was assessed based on the rate of complete wound closure (defined as skin re-epithelialisation without drainage or dressing requirements confirmed at two consecutive visits two weeks apart), time to complete wound closure, incidence of wound breakdown, wound area reduction over time, wound volume reduction over time and health-related quality of life.

More than 75% of patients responded positively to treatment with the LumiHeal treatment. Four patients achieved complete wound closure and three others had an average wound size decrease of approximately 50% over the treatment period. Two patients did not respond to treatment and a last one was discontinued early, due to a non-related serious treatment-emergent adverse event (pneumonia). The LumiHeal treatment also had a positive impact on wound bed preparation, following the treatment initiation. Almost two thirds (62.5%) of patients, at one point during the study, could have been candidates for skin graft. Quality of life was also improved throughout the study.

No case of wound dehiscence was observed during the follow-up period in the patients whose ulcers had achieved full closure.

The safety profile was also excellent, with a total of four treatment-emergent related adverse events. None led to study discontinuation nor required any special intervention. There was no treatment-emergent related serious adverse event.

A pilot study used LumiHeal in 16 chronic stage II and III pressure ulcers. These wounds had been present for longer than three months and previously failed to progress using two or more

established treatment regimens²². The LumiHeal treatment was used twice weekly in 15 wounds and once weekly in one wound.

The patient receiving once-weekly treatment achieved wound closure within three weeks, despite the wound having been present for three months. Of the 15 wounds treated twice weekly, seven (46.7%) achieved closure during the treatment period, while a further four (26.7%) demonstrated strong clinical improvement and progress toward wound closure. As well as being evaluated for size, the wounds were assessed against other criteria and all wounds in the study continued to develop healthy granulation tissue throughout the study period. The study results showed that patients with complex wounds, especially those who have failed to progress previously using multiple surgical and medical treatments, can be successfully managed.

Other BioPhotonic systems have been used for facial rejuvenation and for the treatment of acne vulgaris, with proven safety and efficacy data^{23,24}.

Case study with LumiHeal

We present from the previously mentioned pilot study a case of a 68-year-old male with a 10-year history of DM II, significant EtOH (ethanol/ alcohol) consumption and severe atherosclerotic disease of both lower extremities, leading to a right below-knee amputation seven years prior. The patient now presented with an 18-week history of a non-healing ulcer on the dorsum of his left foot. The patient had been seen by numerous consultants during this time period.

At baseline he was managed with saline cleansing, paste for wound protection and bi-monthly visits

to his physicians. As the wound continued to increase in size, he was managed with a variety of hydrogel and hydrocolloid substrates. The wound was cleared of excess fibrin either mechanically (whirlpool) or via direct excision when deemed necessary. There was no presence of osteomyelitis during this period.

Given the critical stage of the wound and previous below-knee amputation, the patient was concurrently managed by infectious disease specialists, dermatologists, a vascular surgeon and a plastic surgeon. The patient was deemed not to be a candidate for any further surgical or radiological procedures, as his below-knee blood supply was limited to a minor arterial collateral circulation.

At the initial evaluation, the patient presented with a 1.4cm² ulceration, with a wound perimeter of 44mm and a depth of 5mm on the dorsum of his left foot. This progressed to 1.6cm² with a perimeter of 48mm and a depth of 6mm two weeks following the initial evaluation.

The patient's wound at Week 12 showed a 44% reduction in wound size compared to baseline. The wound went on to close completely in the two weeks following cessation of treatments (Week 25). During the treatment period, the patient did not experience any treatment-related adverse event.

Potential cost benefits of LumiHeal

In dealing with chronic and complex wounds, such as pressure ulcers, venous leg ulcers and diabetic foot ulcers, it is well documented that these wounds are costly to manage as well as often having an adverse effect on patients' quality of life²⁵.

It is estimated that approximately 200,000 patients in the UK suffer from a chronic wound²⁶. Depending on the type and cause of the wound, management can involve various treatments and therapies that are not effective. Low healing rates suggest that standard care is frequently insufficient to promote healing of chronic wounds. Significant cost savings, as well as patient benefits, could be achieved if more rapid and complete healing in chronic and complex wounds were possible²⁶.

Earlier studies investigating PBM in general have found that healing times may be accelerated using this technology, which could have significant knock-on cost-saving effects. A study of elderly patients with grade II and III pressure ulcers compared a group receiving PBM treatment to those receiving standard treatment only²⁷. The results demonstrated that patients receiving PBM had a 49% higher ulcer healing rate ($p < 0.05$), a shorter time to 50% ($p < 0.05$) and to 90% ($p < 0.01$) wound closure, compared to those receiving standard care. Additionally, those in the PBM treatment group saw a 90% reduction in the mean ulcer area after five weeks, compared to 10 weeks for the standard care group.

This advance in time to healing could represent a significant cost saving in managing chronic wounds and reducing necessary treatment time.

LumiHeal: Frequently asked questions

How should I prepare the wound prior to LumiHeal treatment?

- Remove any dressing being used
- Clean the wound with normal saline water and proceed with debridement whenever necessary

- Combine the contents of the two jars into the largest jar and mix. Apply a 2 mm layer of the mixed gel to the wound with the spatula provided

How long should the gel be illuminated by the multi-LED lamp?

Illumination with the KLOX multi-LED lamp should be performed for 5 minutes. KLOX internal research has shown that with the multi-LED light intensity and at a distance of illumination of 5 cm, 5 minutes is the optimal treatment time

How should the gel be removed?

The LumiHeal gel can be easily and completely removed after the 5-minute illumination period with a spatula, a moist towel or gauze, or via gentle irrigation with saline water

What are the main contraindications of LumiHeal?

There are few contraindications for LumiHeal treatment, but these include:

- Patients taking drugs or products, or who have conditions, known to induce severe photosensitivity reactions
- Subjects with known skin hypersensitivity
- Pregnant or breast-feeding women

Can LumiHeal be considered as PhotoDynamic Therapy (PDT)?

No, LumiHeal is not considered as PDT. The mechanism of action of PDT is based on the local absorption of a photosensitiser, followed by light activation. It generates large amounts of intracellular reactive oxygen species (ROS), much higher than the level of ROS produced by the cells in their normal metabolic activity, leading to cell death. The LumiHeal treatment was designed for the stimulation of the healing processes, as a topical treatment with the oxygen species sequestered within the gel rather than within a target cell. As a consequence

and unlike PDT, LumiHeal has a very strong tolerability profile, and it does not cause the topical side effects associated with PDT.

Recommendations for future practice

The evidence indicates that PBM therapies have a beneficial effect on all stages of healing processes^{4,5} and provide benefits to the patient such as pain relief and accelerated healing time, which could have a beneficial effect on overall quality of life for patients, particularly those living with a chronic wound.

There is a recognised need for further research in this area, along with the development of treatment pathways. The existing evidence already demonstrates that PBM is particularly beneficial in the treatment of chronic wounds and optimises healing outcomes^{15,16,19,26}.

Author details

Andreas Nikolis¹, Giovanni Scapagnini², Marco Romanelli³

1. Associate Professor, Division of Plastic Surgery, University of Montreal, Canada
2. Professor of Clinical Biochemistry, Department of Medicine and Health Science, University of Molise, Italy
3. Professor and Chairman, Department of Dermatology, University of Pisa, Italy

Supported by Klox Technologies. The views expressed in this Made Easy do not necessarily reflect those of the company.

References

1. Kim WS, Calderhead RG. Is light-emitting diode phototherapy (LED-LLLT) really effective? *Laser Ther* 2011;20:205-15
2. Tsibadze A, Chikvaidze E, Katsitadze A et al. Visible light and human skin (review). *Georgian Med News* 2015;46-53
3. Kim HP. Lightening up light therapy: Activation of retrograde signaling pathway by photobiomodulation. *Biomol Ther* 2014;22:491-6
4. Fathabadie FF, Bayat M, Amini A, Bayat M, Rezaie F. Effects of pulsed infra-red low level-laser irradiation on mast cells number and degranulation in open skin wound healing of healthy and streptozotocin-induced diabetic rats. *J Cosmet Laser Ther* 2013;15:294-304
5. Mittermayr R, Osipov A, Piskernik C et al. Blue laser light increases perfusion of a skin flap via release of nitric oxide from hemoglobin. *Mol Med* 2007;13:22-9
6. AlGhamdi KM, Kumar A, Moussa NA. Low-level laser therapy: a useful technique for enhancing the proliferation of various cultured cells. *Lasers Med Sci* 2012;27:237-49
7. Enwemeka CS, Parker JC, Dowdy DS et al. The efficacy of low-power lasers in tissue repair and pain control: a meta-analysis study. *Photomed Laser Surg* 2004;22:323-9
8. Avci P, Gupta A, Sadasivam M et al. Low-level laser (light) therapy (LLLT) in skin: stimulating, healing, restoring. *Semin Cutan Med Surg* 2013;32:41-52
9. Pallotta RC, Bjordal JM, Frigo L et al. Infrared (810-nm) low-level laser therapy on rat experimental knee inflammation. *Lasers Med Sci* 2012;27:71-78
10. Oliveira MC Jr, Greiffo FR, Rigonato-Oliveira NC et al. Low level laser therapy reduces acute lung inflammation in a model of pulmonary and extrapulmonary LPS-induced ARDS. *J Photochem Photobiol B* 2014;134:57-63
11. Chen AC, Arany PR, Huang YY et al. Low-level laser therapy activates NF- κ B via generation of reactive oxygen species in mouse embryonic fibroblasts. *PLoS One* 2011;6:e22453
12. Arany PR, Nayak RS, Hallikerimath S et al. Activation of latent TGF- β 1 by low-power laser in vitro correlates with increased TGF- β 1 levels in laser-enhanced oral wound healing. *Wound Repair Regen* 2007;15:866-74
13. Cury V, Moretti AI, Assis L et al. Low level laser therapy increases angiogenesis in a model of ischemic skin flap in rats mediated by VEGF, HIF-1 α and MMP-2. *J Photochem Photobiol B* 2013;125:164-70
14. Werdin F, Tennenhaus M, Schaller H et al. Evidence-based management strategies for treatment of chronic wounds. *Eplasty* 2009;9:e19
15. Minatel DG, Frade MA, França SC, Enwemeka CS. Phototherapy promotes healing of chronic diabetic leg ulcers that failed to respond to other therapies. *Lasers Surg Med* 2009;41:433-41
16. Medenica L, Lens M. The use of polarised polychromatic non-coherent light alone as a therapy for venous leg ulceration. *J Wound Care* 2003;12:37-40
17. Caetano KS, Frade MA, Minatel DG et al. Phototherapy improves healing of chronic venous ulcers. *Photomed Laser Surg* 2009;27:111-8
18. Landau Z, Migdal M, Lipovsky A, Lubart R. Visible light-induced healing of diabetic or venous foot ulcers: a placebo-controlled double-blind study. *Photomed Laser Surg* 2011;29:399-404
19. Dini V, Janowska A, Panduri S et al. Preliminary evaluation of biophotonic therapy in chronic wounds. Poster presentation, 2016
20. Burroughes D, Deveny E, Desrosiers E. BioPhotonics: a novel approach to the treatment and regeneration of wounds on and off the battlefield. Poster presentation, 2013
21. Nikolis A, Grimard D, Pesant Y et al. A prospective case series evaluating the safety and efficacy of the KLOX BioPhotonic System in venous leg ulcers. In press
22. Andreas N, Spiros P, Aikaterini K et al. Evaluation of KLOX BioPhotonic therapy on Grade II-III pressure sores. Poster presentation, 2016
23. Nikolis A, Bernstein S, Kinney B. A randomized, placebo-controlled, single-blinded, split-faced clinical trial evaluating the efficacy and safety of KLOX-001 gel formulation with KLOX light-emitting diode light on facial rejuvenation. *Clin Cosmet Investig Dermatol* 2016;9:115-25
24. Antoniou C, Dessinioti C, Sotiriadis D et al. A multicenter, randomized, split-face clinical trial evaluating the efficacy and safety of chromophore gel-assisted blue light phototherapy for the treatment of acne. In press
25. Espicom Business Intelligence. The Global Advanced Wound Care Market to 2017. August 2012
26. Posnett J, Franks PJ (2008) The burden of chronic wounds in the UK. *Nursing Times* 2008;104: 3, 44-5
27. Schubert V. Effects of phototherapy on pressure ulcer healing in elderly patients after a falling trauma: a prospective, randomized, controlled study. *Photodermatol Photoimmunol Photomed* 2001;17(1): 32-8

Summary

PBM is particularly suited to managing chronic wounds, as studies indicate that healing rates are improved when compared to treatment with standard therapies only^{15,16,19,26}.

KLOX LumiHeal novel treatment is a new approach that should be considered in future as a therapy option for patients with wounds that have failed to respond within the expected timeframe to standard therapies.