



Coming Soon!

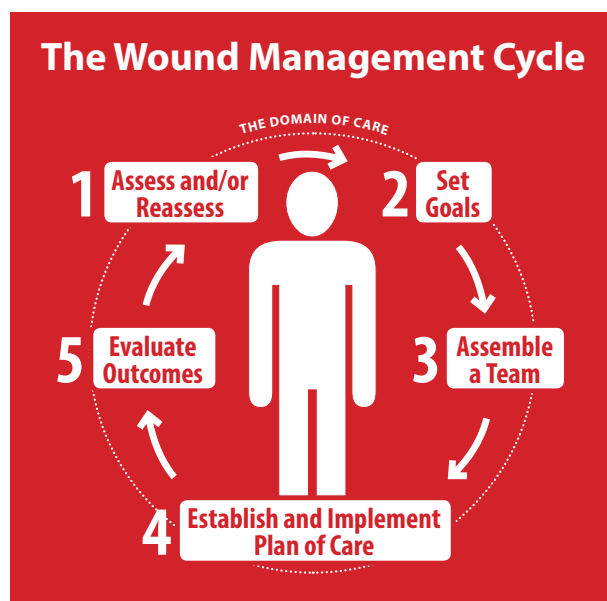Updated

Best Practice Recommendation articles from the Canadian Association of Wound Care

As part of a suite of resources called **Foundations of Best Practice for Skin and Wound Management**, and based on the new Wound Management Cycle, these articles provide a synthesis of Canadian and international guidelines and incorporate the latest evidence into easy-to-use resources for the bedside clinician.

Visit the CAWC website at cawc.net starting in January to view and download:

- Skin: Anatomy, Physiology and Wound Healing
- Best Practice Recommendations for the Prevention and Management of Wounds
- Best Practice Recommendations for the Prevention and Management of Pressure Injuries
- Best Practice Recommendations for the Prevention and Management of Diabetic Foot Ulcers
- Best Practice Recommendations for the Prevention and Management of Skin Tears
- Best Practice Recommendations for the Prevention and Management of Surgical Wound Complications



Evaluation of BioPhotonic Therapy in a non-healing diabetic foot ulcer: A case report

Andreas Nikolis, Stéphane Fauverghe, Denis Vezina, Giovanni Scapagnini

Despite many treatment options, the management of diabetic foot ulcers remains a challenge. Patients with diabetes, in the presence of suboptimal glycemic control and multiple comorbidities, frequently fail to respond to established treatment regimens leading to deterioration and amputation. New therapies, which are safe and effective, are urgently needed. The authors present the case of a 68-year-old male with type 2 diabetes, severe vascular compromise and a non-healing wound on his left foot. A BioPhotonic System was used in the management of this wound without any adverse events. Given its properties and principle of operation, this new modality could represent a new treatment avenue for healthcare professionals involved in the management of complex wounds.

Diabetic foot ulcers (DFU), although largely preventable, are a major source of morbidity, resource utilization and loss of quality of life for patients with diabetes (Ramsey et al, 1999; Valensi et al, 2005). These patients frequently have difficulty with their blood circulation secondary to atherosclerosis and have a 15–25% chance of developing a DFU during their lifetime (Boulton and Armstrong, 2005; Centers for Disease Control and Prevention [CDC], 2011). Currently, approximately 387 million people are living with diabetes worldwide, with an expected increase of 205 million by 2035. What makes the management of this disease process even more complicated is the fact that half of those with the condition are unaware they have diabetes. In 2014, \$612 billion was spent on diabetes worldwide (International Diabetes Federation, 2015; World Health Organization, 2015).

The aetiology of diabetic foot ulcers is multifactorial, as diabetes leads to neuropathy and ischemia of the lower extremities. Apart from hyperglycemia, multiple metabolic abnormalities exist, including high low-density lipoprotein cholesterol (LDL-C) and very-low-density lipoprotein cholesterol (VLDL-C), elevated plasma von Willebrand factor, inhibition of prostacyclin

synthesis, elevated plasma fibrinogen levels and increased platelet adhesiveness (CDC, 2011). The impact of peripheral neuropathy, arterial disease, inflammatory cytokines and foot trauma leads to an increased likelihood of developing a DFU and prevention of healing when one is present (Boulton and Armstrong, 2005; Guo and DiPietro, 2010; Alavi et al, 2014a; 2014b; Canadian Diabetes Association, 2014; International Diabetes Federation, 2015; Lopez, 2014; World Health Organization, 2015). In addition, the presence of poor blood circulation and infection compromises the wound healing process and causes the original ulcer to become chronic, which may eventually lead to amputation when management fails to stop the disease progression (American Diabetes Association, 1999; Alavi et al, 2014a; 2014b).

The management of chronic, non-healing wounds such as DFUs is challenging. Despite current treatment strategies, many wounds fail to heal and persist for months or years. The evolution from an acute to a chronic wound further complicates management. In this context, availability of new, effective and safe therapies that decrease the healing time and severity of ulcers, and that are easy to use and cost-effective would be most welcome.

Citation: Nikolis A, Fauverghe S, Vezina D, Scapagnini G (2016) Evaluation of BioPhotonic Therapy in a non-healing diabetic foot ulcer: A case report. *Diabetic Foot Canada* 4: 25–30

Article points

1. Using low levels of visible light has been shown to positively affect the phases of wound healing.
2. The authors present a case of a man with type 2 diabetes and a non-healing foot ulcer.
3. A BioPhotonic System was used to manage this wound without any adverse events.

Key words

- Non-healing wounds
- Phototherapy
- Ulceration

Authors

Andreas Nikolis, Division of Plastic Surgery, University of Montreal Health Centre, Montreal, Quebec, Canada; Stéphane Fauverghe, KLOX Technologies Inc, Laval, Quebec, Canada; Denis Vezina, KLOX Technologies Inc, Laval, Quebec, Canada; Giovanni Scapagnini, Department of Medicine and Health Sciences, School of Medicine, University of Molise, Campobasso, Italy

“Visible light therapy has historically been used to treat a broad range of skin and soft tissue disorders and is particularly useful in the treatment of chronic wounds.”

The current standard of care for treating DFUs includes achieving and maintaining optimal blood glucose levels, local wound care, frequent debridement, a moist wound environment, prevention and management of infection, adequate nutrition, offloading, vascular reconstruction when indicated, and eventually amputation if the wound continues to progress despite optimal therapy (Bakker et al, 2012; 2016).

Currently available secondary interventions include living skin equivalents, platelet-derived growth factor topical gel and specialized wound dressings. These interventions provide moderate improvement over standard of care in approximately 15–20% of cases, but are often expensive and time-consuming (Margolis, 1999). Other treatment modalities such as negative pressure wound therapy, hyperbaric oxygen therapy, low laser therapy, ultrasound, electrotherapy and electromagnetic therapy have been tried but there is insufficient evidence to support their routine use in diabetic foot ulcers and additional research is needed (Cullum et al, 2001; Samson et al, 2004; Reddy et al, 2008; Sobanko and Alster, 2008; Thrackham et al, 2008; Ubbink et al, 2008; Blume et al, 2011).

Physical examination of a DFU may demonstrate typical and atypical presentations in patients with long-standing disease. The progression of a superficial wound or blister to full depth ulceration can be quick and frequently asymptomatic, especially when loss of protective sensation ensues. Unlike neuropathic ulcers which present frequently on the plantar aspect of the foot, ischemic and neuroischemic ulcerations can occur on any portion of the diabetic foot (Canadian Diabetes Association, 2014). Alternatives and new technologies for the management of such difficult wounds are necessary to prevent the significant complications associated with this disease entity.

One novel and promising treatment is the BioPhotonic System (KLOX Technologies) presented in this article.

The BioPhotonic System

The BioPhotonic System is an innovative treatment for wound healing and skin disorders, and consists of two medical devices: the Photo Converter Wound Gel (primary device) and the Multi-Light Emitting

Diode lamp (secondary device). The topical gel contains specific chromophores, which are not absorbed by the skin, but when excited with the LED lamp they release photons that comprise wavelengths in the spectra of visible light, ranging from 400nm to 610nm, for example. It is known that these low-energy photons show beneficial effect on promoting wound healing.

A variety of in vitro and in vivo tests (GLP and non-GLP) have been performed with the BioPhotonic System, including cytotoxicity and genotoxicity studies, rat skin flap model, rat acute incisional wound healing model, dermal irritation studies in rabbits along with toxicity studies in rats and mini pigs (KLOX Technologies internal data).

Relevant mechanical, electrical, reliability and performance tests were also conducted. In addition, the safety of the gel ingredients has been extensively evaluated. Overall, there are no safety concerns reported in the preclinical tests performed to date. The safety profile of this BioPhotonic System has also been demonstrated and confirmed in the context of different clinical trials conducted in humans, with no treatment-related serious adverse event reported.

Light therapy

Visible light therapy has historically been used to treat a broad range of skin and soft tissue disorders and is particularly useful in the treatment of chronic wounds. The possibility of using visible light to trigger non-thermal, non-cytotoxic, biological reactions through photochemical events has been defined as photobiomodulation (PBM; Kim et al, 2014). PBM is based on evidence that light photons are able to activate photoacceptors in non-photosensitive tissue cells (ie, extra-ocular) that consequently induce molecular cascades, modulating several aspects of cell biology. Photoreceptors include cytochrome c oxidase, cryptochromes, and opsin family proteins, and they are widely expressed in different cell types, including skin and immune cells.

Physiological and, ultimately, therapeutic effects of PBM have been widely explored in wound healing by using different low level energy light sources, including low-level laser, light-emitting diode (LED) and broad band visible light lamps.

The use of low levels of visible light has been shown to positively affect the phases of wound

healing. In the inflammatory phase, low-level laser irradiation promotes proliferation and degranulation of mast cells (Fathabadie et al, 2013). In the proliferative phase, low-level laser therapy enhances proliferation of various cell lines, including fibroblasts, keratinocytes, osteoblasts, and chondrocytes, and induces matrix synthesis (AlGhamdi et al, 2012). In the maturation phase, low-power laser phototherapy improves reorganization and remodelling of wounds and also restores functional architecture of repaired tissues (Enwemeka et al, 2004).

Additional downstream events promoting wound healing through low-dose light therapies are prevention of apoptosis (cell death), increase in blood flow, and stimulation of angiogenesis, as well as increases in adenosine triphosphate and cyclic adenosine monophosphate (Avci et al, 2013). Furthermore, skin exposure to low-level light treatment may start a series of biochemical reactions that result in the production of nitric oxide, a vasodilator and powerful pain reliever, and an anti-inflammatory agent (Mittermayr et al, 2007).

It has also been shown that photobiomodulation events may regulate vascular endothelial growth factor, enhancing the formation of new vessels and improving the healing of skin (Cury et al, 2013). In summary, light treatments can lead to modulation of transcription factors capable of coordinating a wide range of beneficial responses in wound healing.

Another important factor activated by photobiomodulation mechanisms is the transforming growth factors- β (TGF- β). TGF- β plays a crucial role in the proliferation, resolution, and remodelling of the wound tissue by promoting keratinocytes, endothelial, and fibroblast cell migration (Arany et al, 2007).

Several clinical studies have been conducted to investigate low energy light treatments in the management of several skin conditions, including rejuvenation of photoaged skin, acne, skin inflammation and wound healing (Weiss et al, 2005; Goldberg et al, 2006; Lim et al, 2007; Nikolis et al, 2016; Antoniou et al, 2016).

Case report

We present the case of a 68-year-old male with a 10-year history of type 2 diabetes as well as a significant history of previous alcohol consumption. The

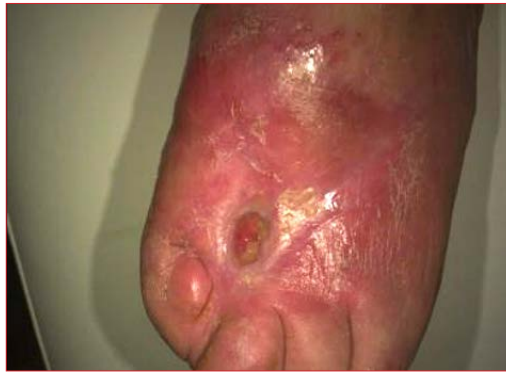

Figure 1. Initial evaluation. Note previous amputation of great toe secondary to osteomyelitis.

patient is known for severe atherosclerotic disease of both lower extremities, having undergone a previous fem-fem bypass. The patient developed significant ischemia of his right lower extremity despite multiple surgical and non-surgical interventions, eventually requiring a below-knee amputation 7 years earlier.

The patient now presented with an 18-week history of a non-healing ulcer on the dorsum of his left foot. The patient was followed by numerous consultants during this time period. At baseline he was managed with saline cleansing, paste for wound protection and bimonthly visits to his physicians. As the wound continued to increase in size, he was managed with a variety of hydrogel and hydrocolloid substrates. The wound was cleared of excess fibrin mechanically (whirlpool) or with direct excision when deemed necessary. Furthermore, the patient received multiple courses of antibiotics for cellulitis. There was no presence of osteomyelitis during this period.

The treating physician requested that the patient be evaluated repeatedly by the infectious disease specialists, dermatologists, a vascular surgeon and a plastic surgeon. Following vascular surgery evaluation, the patient was deemed not to be a candidate for any further surgical or radiological procedures because his below-knee blood supply was limited to a minor arterial collateral circulation alone.

Given the patient's history of multiple failed treatment regimens in light of a previous contralateral limb amputation, a decision was made to treat his wound with the current BioPhotonic System due to a lack of alternatives and constant

Page points

1. Using low levels of visible light has been shown to positively affect the phases of wound healing.
2. Low levels of visible light promote proliferation and degranulation of mast cells in the inflammatory phase.
3. In the proliferative phase, low levels of visible light enhance proliferation of cell lines.
4. In the maturation phase, low levels of visible light improve reorganization and remodelling of wounds, and also restores functional architecture of repaired tissues.

“Management of DFUs is often complicated by poor diabetes control, recurrent infections, slow onset and altered patterns of wound closure, and repeated trauma to the wound.”

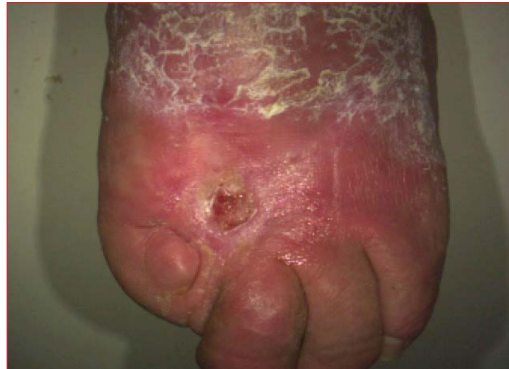

Figure 2. Week 12. Note the decrease in wound depth and the presence of granulation tissue.

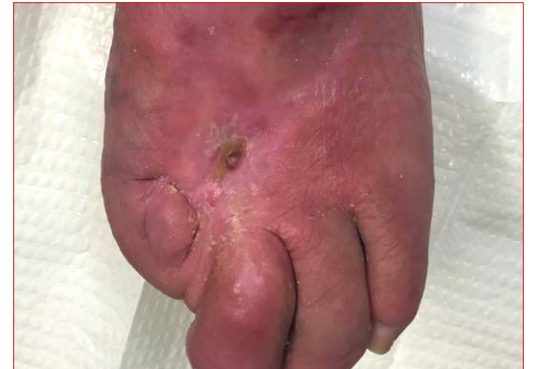

Figure 3. Wound closed, with epithelialization of wound base.

progression of the ulceration in a non-surgical candidate. The patient was compliant with all visits and there was no relapse in his alcohol consumption.

At the initial evaluation, he presented with a 1.4 cm² ulceration with a wound perimeter of 44 mm and a depth of 5 mm on the dorsum of his left foot. This progressed to 1.6 cm² with a perimeter of 48 mm with a depth of 6 mm 2 weeks following the initial evaluation (*Figure 1*).

Wound surface evaluation (mean change in wound area over time) was performed via a standardized wound measurement grid backed up by standard digital images. Wound size and volume assessments were captured with the Silhouette™ Imaging System, an imaging device linked to a computerized system, allowing wound pictures and assessments of key characteristics (area, volume, depth, etc). This system was chosen for its ease of use, its reliability between investigators and its 3D laser light-technology that allows assessment of the volume of the wound's underlying anatomy (Romanelli et al, 2008).

The patient initially underwent treatment of his wound twice weekly for a period of 8 weeks. During this treatment cycle, a thin layer (2 mm) of Photo Converter Wound Gel was applied on the wound. The Multi-LED Lamp was then turned on for 5 minutes to illuminate the chromophores within the gel. The gel was then removed and a non-adherent dressing was applied. The patient's wound was managed between treatments with daily saline irrigation and plain gauze dressing changes. Following completion of this treatment cycle, the patient received a 1-week holiday in which the wound was managed conservatively in the

same fashion without any BioPhotonic treatment. Following this window, the patient underwent further bi-weekly treatments for a further 14 weeks. *Figure 2* shows the wound at week 12, showing a 44% reduction in wound size vs baseline.

At the end of the treatment cycle, the patient's wound had a surface area of 0.3 cm², a 23 mm perimeter, and a depth that was not measurable by the device (approximately 1 mm; *Figure 3*).

During the treatment period, the patient did not experience any treatment-related adverse events. The wound closed completely in the 2 weeks following cessation of treatments. Evaluation of the wound surface area during the study period demonstrated a major decrease in surface area beginning at week 10 (*Figure 4*).

Discussion

Management of DFUs is often complicated by poor diabetes control, recurrent infections, slow onset and altered patterns of wound closure, and repeated trauma to the wound.

Many theories of causality exist in the pathogenesis of chronic wounds. Several key factors play a role, including modification of normal cellular processes, ischemia-reperfusion injuries and colonization by bacterial, fungal or other micro-organisms (Falanga, 2004; Mustoe, 2004). DFUs are further impacted by arterial insufficiency and diabetic neuropathy. In parallel, nerve damage results from interacting metabolic abnormalities and can be worsened by disease of the vasa nervosum affecting peripheral sensation, innervation of the foot muscles and fine vasomotor control of the pedal circulation, which are also

involved in the disease (Fonder et al, 2008). Intrinsic (neuropathy, vascular problems, systemic effects of DM) and extrinsic factors (wound infection, callus formation, pressure, humidity) play a role in the progression of the disease.

Further impediments to wound healing include macrovascular (atherosclerosis) and microvascular ischemia structural (thickened basement membrane, capillary wall fragility and thrombosis) as well as functional (vasomotor neuropathy with defective microvascularisation and abnormal endothelial function). Furthermore, biofilms, or collections of bacterial colonies surrounded by a protective coat of polysaccharides, increase bacterial resistance to antibiotherapy.

In the management of DFU, debridement has a multi-fold impact: the mechanical act will frequently decrease the bacterial burden in the wound as well as the presence of any necrotic tissue. Debridement of slough, excess exudate and callus will also promote a healthier wound environment (Browne et al, 2001). Following debridement alone, most DFUs will not progress to wound closure. The intrinsic characteristics of the wound will rarely be reversed. Although debridement leads to an improved environment, a treatment impacting collagenesis and preventing a significant bacterial load is essential.

The BioPhotonic platform helps wound management through multiple actions. First, in vitro evidence demonstrates that the combination of these two medical devices allows for the diminution of bacteria in the wound, typically colonized by *Pseudomonas aeruginosa* and *Staphylococcus*. Anti-bacterial activity against multiple Gram-positive and Gram-negative bacterial strains will improve the equilibrium of grossly colonized wounds. This is important considering evidence that bacterial loads in excess of 105 organisms per gram of tissue are said to impede wound healing (Robson, 1997; Browne et al, 2001). Furthermore, infections of chronic wounds are polymicrobial and the continuum between mild-moderate colonization and the beginning of infection are blurred.

Secondly, evidence from multiple studies in outcomes using the Biophotonic system demonstrated a strong propensity for an acute and early phase of myofibroblast and macrophage

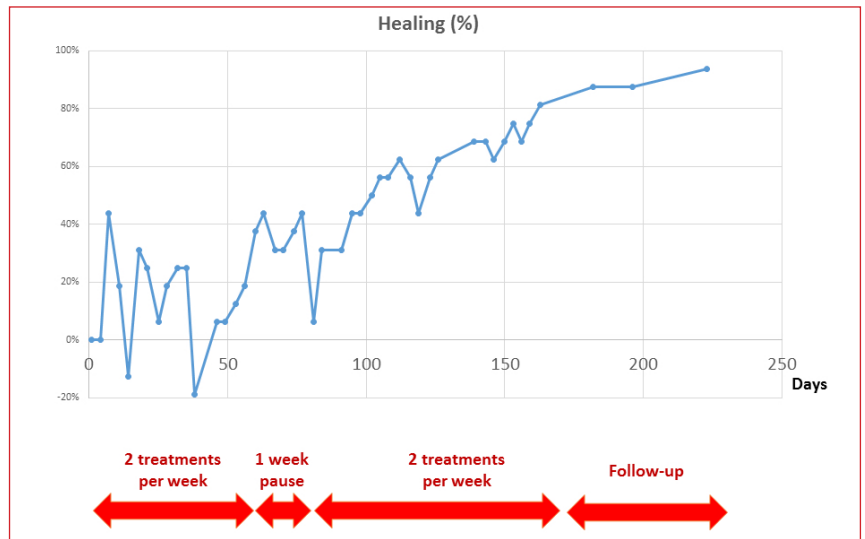


Figure 4. Patient's wound healing (percentage) over time.

deposition, clearly altering the status of the previously stagnant wound from baseline (Nikolis et al, 2016). The net result is a synergistic effect of a healthier wound environment and proliferation of cells leading to collagen deposition.

Conclusion

A passive approach in the management of DFUs frequently leads to irreversible and unsalvageable wounds. The architecture for normal wound healing no longer exists in these patients because deregulation of key processes occurs when one or more intrinsic and/or extrinsic factors impact the wound. An external treatment regimen is required in promoting progression through the phases of wound healing. The BioPhotonic System offers a significant chance for the wound to reach such a state by impacting bacterial burden and collagenesis. ■

Alavi A, Sibbald RG, Mayer D et al (2014a) Diabetic foot ulcers: Part I. Pathophysiology and prevention. *J Am Acad Dermatol* **70**(1): 1.e1-1.e18

Alavi A, Sibbald RG, Mayer D et al (2014b) Diabetic foot ulcers: Part II. Management. *J Am Acad Dermatol* **70**(1): 21.e1-21.e24

AlGhamdi KM, Kumar A, Moussa NA (2012) Low-level laser therapy: a useful technique for enhancing the proliferation of various cultured cells. *Lasers Med Sci* **27**(1): 237-49

Antoniou C, Dessinioti C, Sotiriadis D et al (2016) A multicenter, randomized, split-face clinical trial evaluating the efficacy and safety of chromophore gel-assisted blue light phototherapy for the treatment of acne. *Int J Dermatol* Aug 30 [Epub ahead of print]

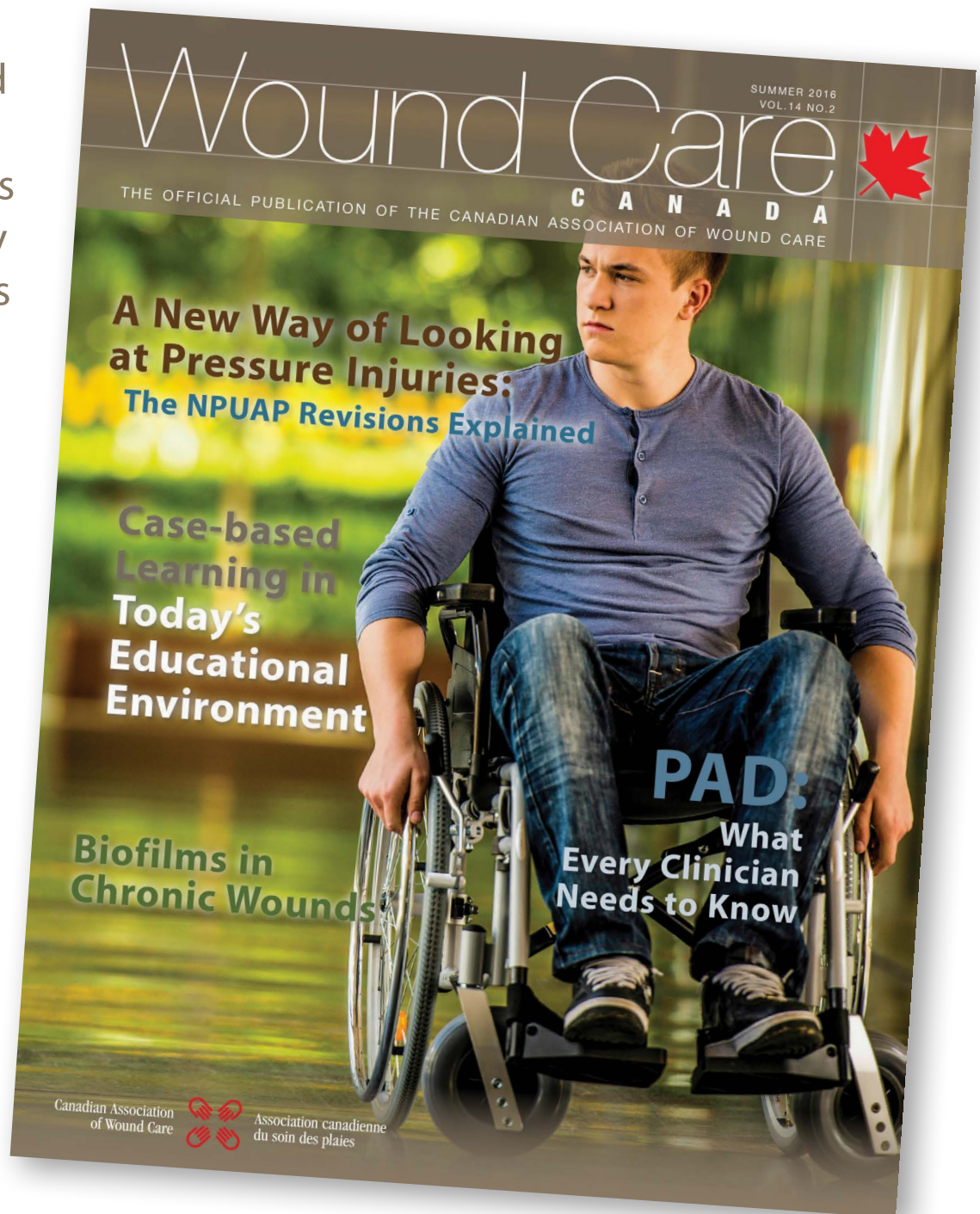American Diabetes Association (1999) Consensus development conference on diabetic foot wound care. *Diabetes Care* **22**(8): 1354-60.

- Arany PR, Nayak RS, Hallikerimath S et al (2007) Activation of latent TGF-beta1 by low-power laser in vitro correlates with increased TGF-beta1 levels in laser-enhanced oral wound healing. *Wound Repair Regen* **15**(6): 866–74
- Avci P, Gupta A, Sadasivam M et al (2013) Low-level laser (light) therapy (LLLT) in skin. *Semin Cutan Med Surg* **32**(1): 41–52
- Bakker K, Apelqvist J, Schaper NC (2012) Practical guidelines on the management and prevention of the diabetic foot 2011. *Diabetes Metab Res Rev* **28**(Suppl 1): 225–31
- Bakker K, Schaper NC, Lipsky BA et al (2016) The 2015 IWGDF guidance documents on prevention and management of foot problems in diabetes: development of an evidence-based global consensus. *Diabetes Metab Res Rev* **32**(Suppl 1): 2–6
- Blume P, Driver VR, Tallis AJ et al (2011) Formulated collagen gel accelerates healing rate immediately after application in patients with diabetic neuropathic foot ulcer. *Wound Repair Regen* **19**(3): 302–8
- Boulton AJ, Armstrong DG (2015) Diabetic foot and ulceration: epidemiology and pathophysiology. In: Falabella AF, Kirsner RS (eds). *Wound Healing*. Taylor & Francis, London
- Browne AC, Vearncombe M, Sibbald RG (2001) High bacterial load in asymptomatic diabetic patients with neurotrophic ulcers retards wound healing after application of Dermagraft. *Ostomy Wound Manage* **47**(10): 44–9
- Canadian Diabetes Association (2014) *An economic tsunami: the cost of diabetes in Canada*. Available at: <http://bit.ly/2f1ILzc> (accessed 29.11.16)
- Centers for Disease Control and Prevention (2011) National diabetes fact sheet: national estimates and general information on diabetes and prediabetes in the United States, 2011. CDC, Atlanta (GA)
- Cullum N, Nelson EA, Flemming K, Sheldon T (2001) Systematic reviews of wound care management: (5) beds; (6) compression; (7) laser therapy, therapeutic ultrasound, electrotherapy and electromagnetic therapy. *Health Technol Assess* **5**(9): 1–221
- Cury V, Moretti AI, Assis L et al (2013) Low level laser therapy increases angiogenesis in a model of ischemic skin flap in rats mediated by VEGF, HIF-1 α and MMP-2. *J Photochem Photobiol B* **125**: 164–70
- Enwemeka CS, Parker JC, Dowdy DS, Harkness EE, Sanford LE, Woodruff LD (2004) The efficacy of low-power lasers in tissue repair and pain control: a meta-analysis study. *Photomed Laser Surg* **22**(4): 323–9
- Falanga V (2004) The chronic wound: impaired healing and solutions in the context of wound bed preparation. *Blood Cells Mol Dis* **32**(1): 88–94
- Fathabadi FF, Bayat M, Amini A et al (2013) Effects of pulsed infra-red low level-laser irradiation on mast cells number and degranulation in open skin wound healing of healthy and streptozotocin-induced diabetic rats. *J Cosmet Laser Ther* **15**(6): 294–304
- Fonder MA, Lazarus GS, Cowan DA et al (2008) Treating the chronic wound: A practical approach to the care of nonhealing wounds and wound care dressings. *J Am Acad Dermatol* **58**(2): 185–206
- Goldberg DJ, Russell BA (2006) Combination blue (415 nm) and red (633 nm) LED phototherapy in the treatment of mild to severe acne vulgaris. *J Cosmet Laser Ther* **8**(2): 71–5
- Guo S, DiPietro LA (2010) Factors affecting wound healing. *J Dent Res* **89**(3): 219–29
- Huang YY, Sharma SK, Carroll J, Hamblin MR (2011) Biphasic dose response in low level light therapy – an update. *Dose Response* **9**(4): 602–18
- International Diabetes Federation (2015) IDF Diabetes Atlas Seventh Edition Update. International Diabetes Federation. Available at: <http://www.idf.org/worlddiabetesday/toolkit/gp/facts-figures> (accessed 20.10.2016)
- Iordanou P, Baltopoulos G, Giannakopoulou M et al (2002) Effect of polarized light in the healing process of pressure ulcers. *Int J Nurs Pract* **8**(1): 49–55
- Kim HP (2014) Lightening up light therapy: activation of retrograde signaling pathway by photobiomodulation. *Biomol Ther (Seoul)* **22**(6): 491–6
- KLOX Technologies Inc (2015) Data on file
- Lim W, Lee S, Kim I et al (2007) The anti-inflammatory mechanism of 635 nm light-emitting-diode irradiation compared with existing COX inhibitors. *Lasers Surg Med* **39**:614–21.
- Lopez Rowe V, Khardoni R (2014) Diabetic ulcers. Medscape
- Margolis DJ (1999) Healing of diabetic neuropathic foot ulcer receiving standard treatment. *Diabetes Care* **22**(5): 692–5
- Mittermayr R, Osipov A, Piskernik C et al (2007) Blue laser light increases perfusion of a skin flap via release of nitric oxide from hemoglobin. *Mol Med* **13**(1–2): 22–9
- Mustoe T (2004) Understanding chronic wounds: a unifying hypothesis on their pathogenesis and implications for therapy. *Am J Surg* **187**(5A): 65S–70S
- Nikolis A, Bernstein S, Kinney B et al (2016) A randomized, placebo-controlled, single-blinded, split-faced clinical trial evaluating the efficacy and safety of KLOX-001 gel formulation with KLOX light-emitting diode light on facial rejuvenation. *Clin Cosmet Investig Dermatol* **9**: 115–25
- Nikolis A, Grimard D, Pesant Y et al. A prospective case series evaluating the safety and efficacy of the KLOX BioPhotonic System in venous leg ulcers. In press.
- Ramsey SD, Newton K, Blough D et al (1999) Incidence, outcomes, and cost of foot ulcers in patients with diabetes. *Diabetes Care* **22**(3): 382–7
- Reddy M, Gill SS, Kalkar SR et al (2008) Treatment of pressure ulcers: A systematic review. *JAMA* **300**(22): 2647–62
- Romanelli M, Dini V, Rogers LC et al (2008) Clinical evaluation of a wound measurement and documentation system. *Wounds* **20**(9): 258–64
- Robson MC (1997) Wound infection. *Surg Clin North Am* **77**(3): 637–50
- Samson DJ, Lefevre F, Aronson N (2004) Wound-healing technologies: low level laser and vacuum assisted closure. *Evid Rep Technol Assess (Summ)* (111): 1–6
- Sobanko JF, Alster TS (2008) Efficacy of low-level laser therapy for chronic cutaneous ulceration in humans: a review and discussion. *Dermatol Surg* **34**(8): 991–1000
- Sutherland JC (2002) Biological effects of polychromatic light. *Photochem Photobiol* **76**(2): 164–70
- Thrackham JA, McElwain DL, Long RJ (2008) The use of hyperbaric oxygen therapy to treat chronic wounds: A review. *Wound Repair Regen* **16**(3): 321–30
- Ubbink DT, Westerbos SJ, Nelson EA, Vermeulen H (2008) A systematic review of topical negative pressure therapy for acute and chronic wounds. *Br J Surg* **95**(6): 685–92
- Valensi P, Girod I, Baron F et al (2005) Quality of life and clinical correlates in patients with diabetic foot ulcers. *Diabetes Metab* **31**(3 Pt 1): 263–71
- Weiss RA, McDaniel DH, Geronemus RG, Weiss MA (2005) Clinical trial of a novel non-thermal LED array for reversal of photoaging. *Lasers Surg Med* **36**(2): 85–91
- World Health Organization (2015) Diabetes. Available at: <http://www.who.int/mediacentre/factsheets/fs312/en/> (accessed 29.11.16)

Read *Wound Care Canada* online!

Canada's premier wound management magazine offers full interactivity and easy access from your computer or mobile device. And now all articles can be accessed and downloaded individually.

Read the most up-to-date wound management information anywhere, any time.



Visit www.woundcarecanada.ca to view the latest issue.

Canadian Association
of Wound Care



Association canadienne
du soin des plaies

The CAWC is Canada's leading wound-related knowledge mobilization organization.